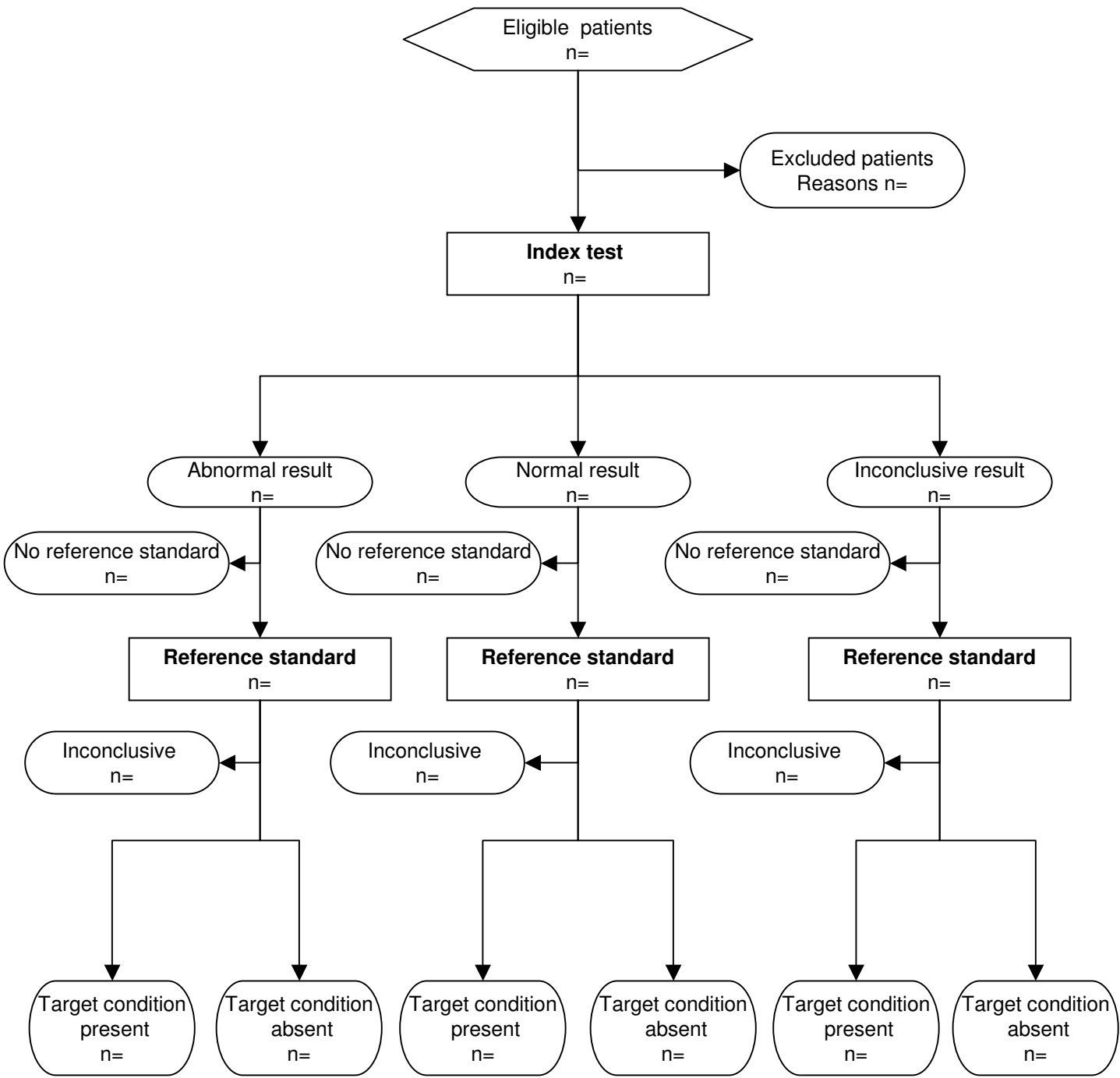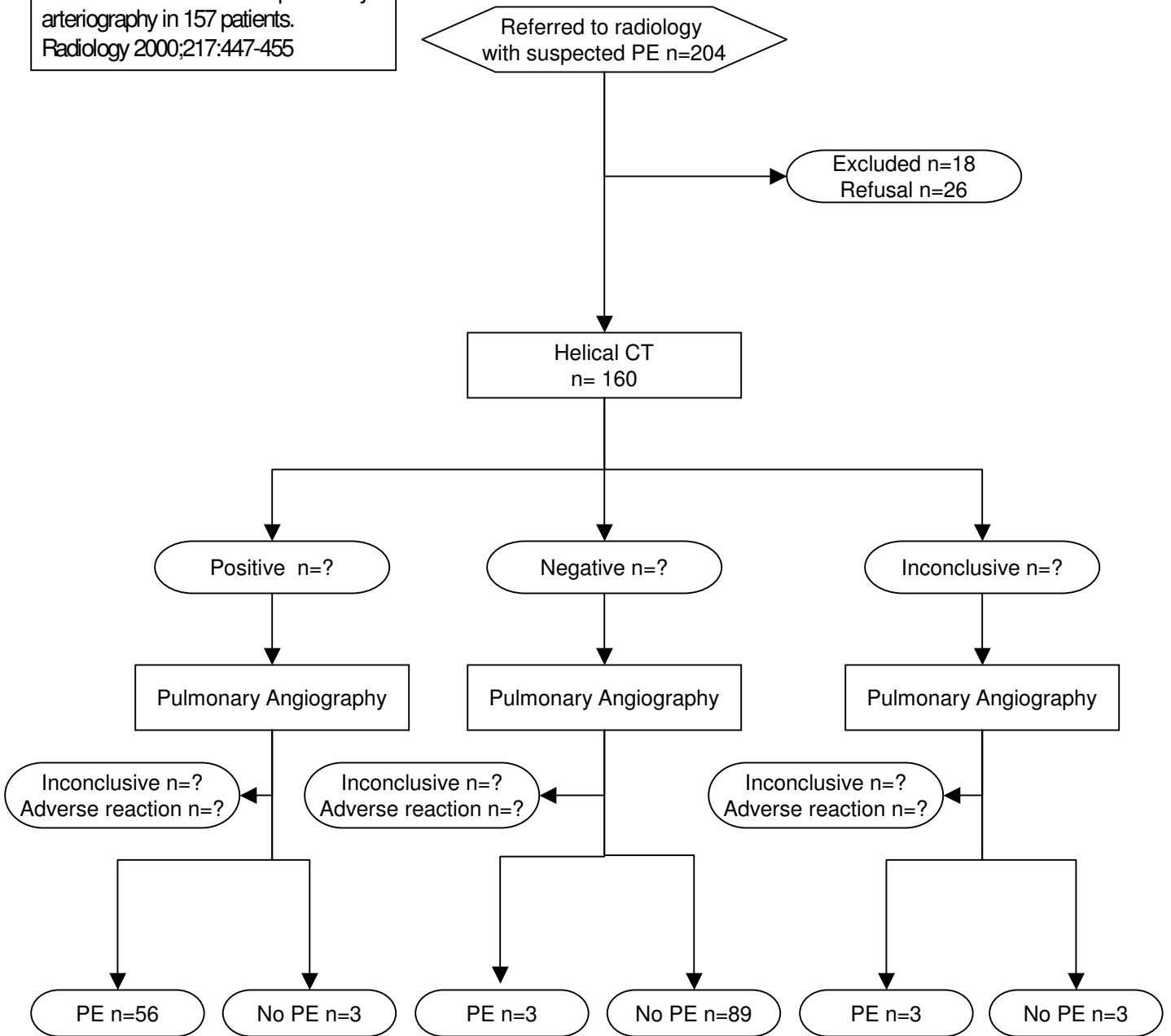


General example

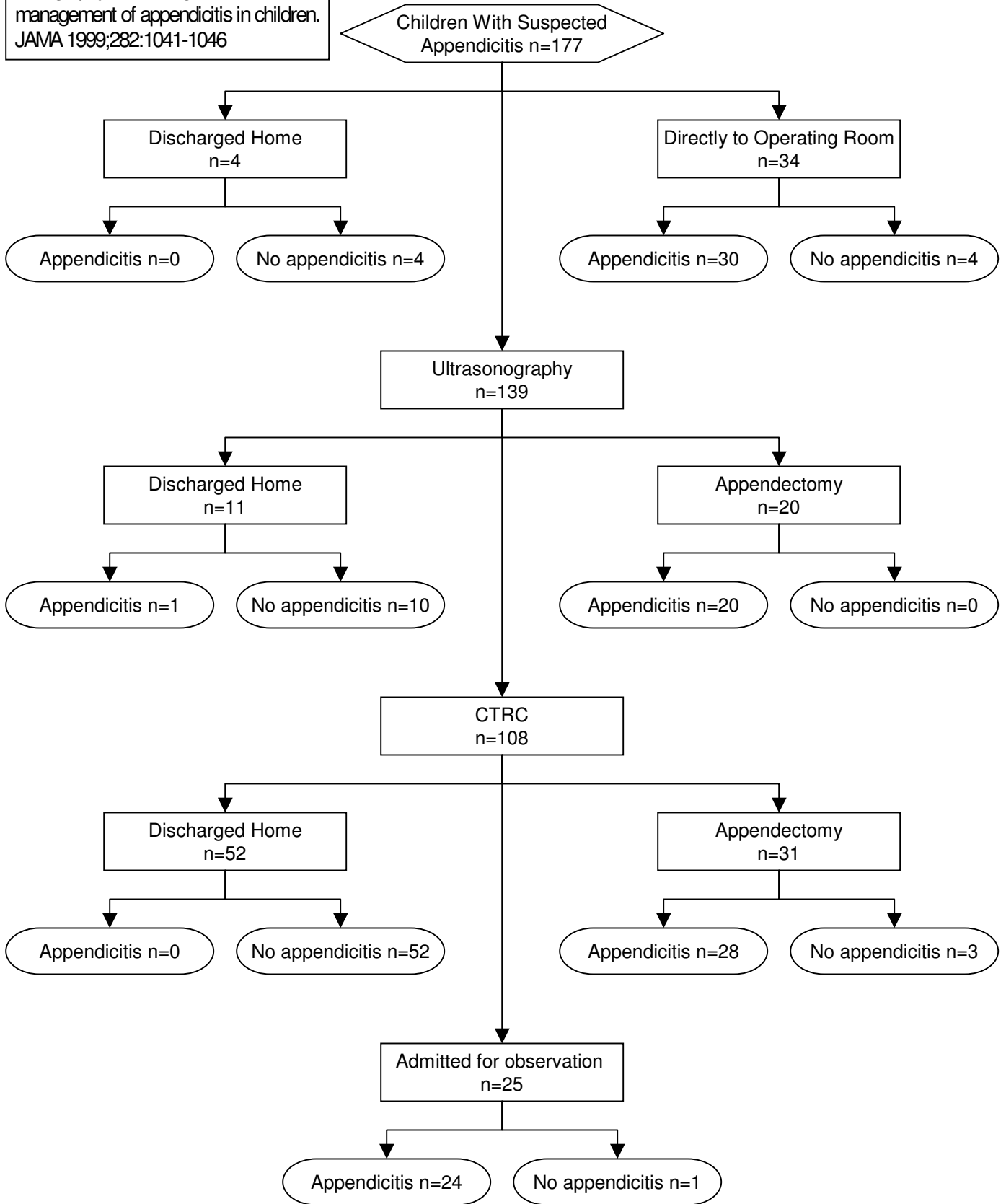


Prototypical flow diagram of a study of diagnostic accuracy.
First official version, January 2003.

Pulmonary embolism detection:
prospective evaluation of dual section
helical CT versus selective pulmonary
arteriography in 157 patients.
Radiology 2000;217:447-455



Ultrasonography and limited computed tomography in the diagnosis and management of appendicitis in children. JAMA 1999;282:1041-1046



Biochemical diagnosis of ventricular dysfunction in elderly patients in general practice: observational study. BMJ 2000;320:9906-8

